

## **SHEEP OESTROSIS (*OESTRUS OVIS*, DIPTERA: OESTRIDAE) IN DAMARA CROSSBRED SHEEP**

**GUNALAN S.<sup>1</sup>, KAMALIAH G.<sup>1</sup>, WAN S.<sup>1</sup>, ROZITA A.R.<sup>1</sup>, RUGAYAH M.<sup>1</sup>, OSMAN M.A.<sup>1</sup>, NABIJAH D.<sup>2</sup> AND SHAH A.<sup>1</sup>**

<sup>1</sup> Regional Veterinary Diagnostic Laboratory Kuantan, Jalan Sri Kemunting 2, Kuantan, Pahang

<sup>2</sup> KTS Jengka Pusat Perkhidmatan Veterinar Jengka

Corresponding author: gunalan@dvs.gov.my

**ABSTRACT.** Oestrosis is a worldwide myiasis infection caused by the larvae of the fly *Oestrus ovis* (Diptera, Oestridae), that develops from the first to the third stage larvae. This is an obligate parasite of the nasal and sinus cavities of sheep and goats. The *Oestrus ovis* larvae elicit clinical signs of cavitary myiasis seen as a seromucous or purulent nasal discharge, frequent sneezing, incoordination and dyspnea. Myiasis in an incidental host may have biological significance towards medical and public health importance if the incidental host is man. This infection can result in signs of generalized disease, causing serious economic losses in sheep and goat reared for meat and dairy production. Due to the large numbers of small ruminants imported into Malaysia from countries which are endemic with oestrosis, precautionary measures should be exercised to prevent this infection from establishing here. In 2009, there was a report of respiratory distress (pneumonic sign) accompanied by high mortality in Damara sheep that was imported from Australia. Investigations showed the presence of *Oestrus ovis* larvae in affected sheep. The post mortem was conducted in

the field and the larvae were discovered in the tracheal region. The larvae was confirmed as *Oestrus ovis* using the appropriate keys for identification by Zumpt. The carcass showed pulmonary edema with severe congestion of the lungs accompanied by frothy exudation in the bronchus. There were also signs of serious atrophy (heart muscle) and mild enteritis (intestine histopathological examination showed, there was pulmonary congestion and edema, centrilobular hepatic necrosis, renal tubular necrosis and myocardial sarcocystosis. The sheep also showed chronic helminthiasis and *Staphylococcus* spp. was isolated from organ specimens. *Oestrus ovis* infection is rare in Malaysia, as such this case posed as an unusual case for investigation.

*Keywords:* *Oestrus ovis*, Damara sheep, larvae, respiratory sign, myiasis

### **INTRODUCTION**

Larvae of flies belonging to the Oestridae Family and Oestrinae Subfamily include several genera which cause obligatory myiasis in Artiodactyla and Equidae, infesting the nasopharyngeal cavities and

internal organs during their migration. Oestrosis is a regional myiasis caused by larvae of the fly *Oestrus ovis* (Diptera, Oestridae), that develop from the first to the third stage larva which are obligate parasites of the nasal and sinus cavities of sheep and goats.

The larvae are obligatory parasites of nasal and sinus cavities of sheep and goats (Zumpt, 1965). The female are larviparous, depositing a number of first-instar larvae on the edge, or just inside the nostrils of sheep and goats. The peculiar feature of the *O. ovis* female is that it may larviposit while still in flight. In their normal development in sheep, the larvae migrate to the nasal mucosa and nasal and frontal sinuses where they undergo 2 moults. After 2 to 12 months, the fully grown third instar larvae are expelled and pupate on the ground.

This parasite is found worldwide and it is especially widespread in Mediterranean countries of Europe and Africa (Pandey, 1989; Dorchie et al., 2000; Alcaide et al., 2003; Papadopoulos et al., 2006). Despite the high prevalence in these countries and severity of infection, many breeders and veterinary practitioners still remain unaware of the importance of these parasitic agents. The subfamily *Oestrinae mutation* is still unknown. During the last decade, some work on genetics, pathophysiology and immunology was done in France, Italy, Mexico and Spain and a review was published by Hall and Wall (1995).

Extensive use of macrocyclic lactones is modifying parasitic diversity (Otranto and Colwell, 2008), whereas in some areas of

southern Europe an unusually large number of different species of bot fly suggests a high degree of oestrid biodiversity. It seems related to the movement of domestic animals in association with migrating human populations in southern Europe over thousands of years (Otranto et al., 2006). *Oestrus ovis* can thrive in different environments (Horak, 1977; Breev et al., 1980; Pandey and Ouhelli, 1984) and can overwinter in a diapause state, as larvae in the sinu-nasal passages of the host (Cobbett and Mitchell, 1941; Horak, 1981). The ability to adapt in a different environment allows the natural persistence of infestation and the difficulties for its control. Recent surveys have demonstrated the high prevalence of caprine Oestrosis in numerous areas all over the world, 48.3% in India (Jagannath et al., 1989), 31.3% in Mexico (Martinez et al., 1992), 4 % in Argentina (Trezeguet, 1996) and 53.8% in Nigeria (Biu and Nwosu, 1999). So far, there is no case report of *Oestrus ovis* in sheep in Malaysia, a tropical rainforest country where large imports of sheep and goats for breeding and sheep production is carried out regularly.

The *O. ovis* larvae elicit clinical signs of cavitary myiasis as a seromucous or purulent nasal discharge, frequent sneezing, incoordination and dyspnea. This infection can result in signs of generalized disease, causing serious economic losses in sheep and goat herds reared for meat and dairy produce. The development of larvae in the nasal-sinus cavities can cause severe clinical signs such as breathing difficulties,

nasal discharge and emaciation, together with the annoyance caused by the adult flies. This may lead to production and economic losses (Dorchies *et al.*, 1998, 2003). *Oestrus ovis* can severely impair breathing because it induces tenacious nasal discharge to which grass, straw and dust adhere, clogging the air passages. Moreover, the infection may be complicated by sinus tumour and lung abscesses (Dorchies *et al.*, 1993).

Furthermore, several cases of ophthalmic and naso-pharyngeal myiasis have been reported in humans, indicating a public health issue in certain areas (Dar *et al.*, 1980; Masoodi and Hosseini, 2003). The ophthalmomyiasis produced in man by *O. ovis* larvae is restricted to conjunctivae, sclera, eyelids, and lachrymal duct (external ophthalmomyiasis) or the eye ball (internal ophthalmomyiasis) (Hadani *et al.* and Dar *et al.*, 1980; Stulting and Meyer, 1981; Omar *et al.*, 1988; Amir *et al.*, 1993). Myiasis in an incidental host which may have biological significance and can also be of medical and public health importance if the incidental host is a man. Myiasis caused by *O. ovis* may be considered as an occupational disease of shepherds or farmers who usually keep their sheep and goats in close proximity to their dwellings (Amir *et al.*, 1993).

This infection can result in generalized disease, causing serious economic losses in sheep and goat reared for meat and dairy produce. Despite the fact that both animal species can be host of this parasite, infection prevalence and larval burdens are generally

higher in sheep than in goats after either natural or artificial infestation (Duranton *et al.*, 1996). Little is known about the development of immunity but it is possible that some animals are immunodeficient. Respiratory disease are common in sheep and goats and *O. ovis* has been suggested to have an immunosuppressive effect (with consequent association with respiratory pathogens) (Dorchies *et al.*, 1993).

Despite the fact that both animal species can be hosts of this parasite, infection prevalence and larval burdens are generally higher in sheep than in goats after either natural or artificial infestation (Duranton *et al.*, 1996, Papadopoulos *et al.*, 2006), and this is taken to indicate higher susceptibility in sheep.

### History of Case Report

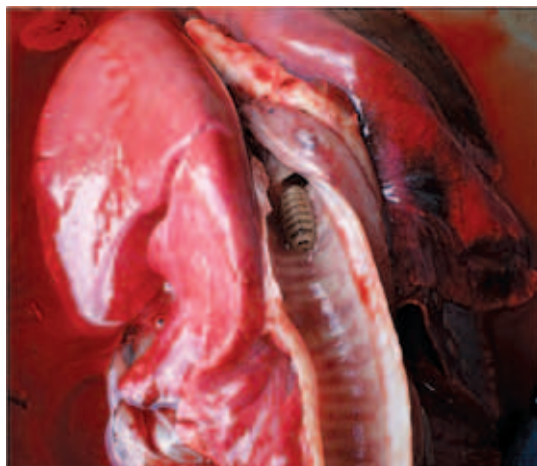In 2009, a case of respiratory distress accompanied by severe mortality was reported in Damara sheep that was recently imported into Malaysia from a neighbouring country. The report involved 25 heads of 7-month-old, female Damara crossbred sheep imported in stages over a period of 4-5. They were sent for breeding purposes to a commercial sheep farm. The sheep were reared using an intensive system where animals were fed grass and pellets. Initially, a few animals exhibited severe respiratory signs indicative of suspected pneumonia. Soon after, the sheep showed signs of respiratory distress such as loud, noisy breathing, poor body scores (severe emaciation), ill thrift and

were unproductive with poor kidding rates. About 10% mortality was reported initially. The flock of sheep were treated with antibiotics by veterinary personnel, and subsequently one of the treated sheep died 4 days after treatment prompting a postmortem. The post mortem exhibited findings of frothy discharge with foamy exudation (especially in the bronchus) with whitish nodules in the trachea. The most significant finding was the discovery of larvae crawling in the tracheal region toward the bronchus region. The tracheal rings showed some congestion. There was severe congestion of lung lobes (involving apex region and diaphragm lobes) and evidence of whitish patches and foamy appearances on the lung surface. Besides that, there was bile impression on the mildly swollen liver. Furthermore, congestion on the serosal surface of the small intestines and capillaries of mesentery was observed. The ingesta in the intestine was dark coloured and had a

foul smell. There was also serous atrophy of the heart coronary fat and generalized moderate congestion in all vital organs. Based on the post mortem and clinical signs exhibited by this flock of sheep, the differential diagnosis made were bacterial pneumonia, viral pneumonia, verminous pneumonia, chronic helminthiasis and malnutrition problem.

## MATERIALS AND METHOD

From the post mortem, the samples were submitted for further examination and disease diagnosis to the Regional Veterinary Diagnosis Laboratory. The samples sent were lung, liver, kidney, heart and spleen. Specimens such as intestine, fecal sample and larvae in normal saline were sent to the laboratory. All other specimen of organs went through detailed examination for gross lesions and bacteriology as well as virology investigation. Simultaneously, larvae and faeces were sent for parasitology



**Figure 1.** Migration of larvae in the lung bronchus & tissue

examination. For histopathology examination, the samples such as lung, liver, heart and kidney tissue were sent in the 10% buffered formalin for examination.

## RESULTS

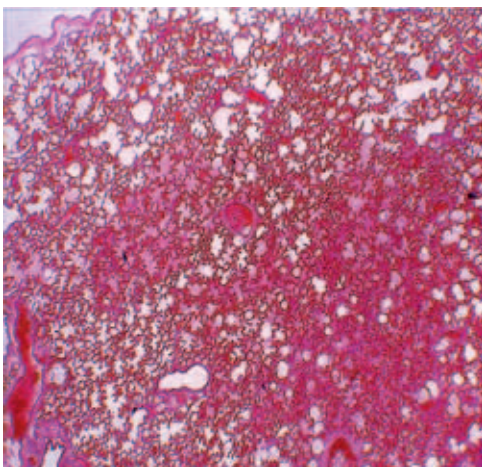
The laboratory diagnosis based on bacteriology and virology, did not reveal any significant result. Bacteriology findings indicated no bacterial growth in the lung and heart tissue. However, there were presence of normal flora growth or opportunistic organisms growth such as *Escherichia coli* from the intestine sample and *Staphylococcus* spp. from the liver tissue. There was no viral isolation from the pooled samples using the tissue culture technique.

As for the parasitology examination, Faecal Egg Count (FEC) detected the presence of helminths eggs and oocysts of coccidia. The faecal sample was positive

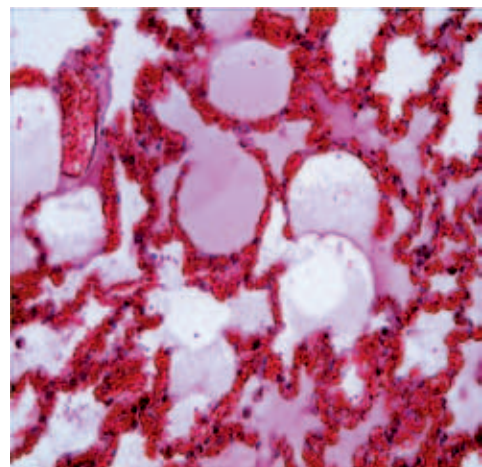
with 100 e.p.g. for *Strongyles* spp. with no larvae recovered from faeces.

The lung surface showed pneumonic lesions along with presence of whitish patches and foamy appearances. The kidney and liver were congested with no significant gross lesions in the heart and spleen.

Histological examination showed that the lung alveolar had collapsed, and the lung was oedematous and congested. There was evidence of congestion, infiltrations of polymorphonuclear inflammatory cells (PMNs) in alveolar interstitium and proteinaceous material inter alveolar. There was cardiac muscle congestion and fragmentation. In the cardiac tissue, the cyst of the *Sarcocystis* spp. parasite was present in the intra cardiac muscle. In the liver tissue, there was presence of necrosis and ballotment of hepatocytes, widening of sinusoid space and red blood cells were found in between sinusoidal space. In the renal tissue, presence of picnotic nucleus of

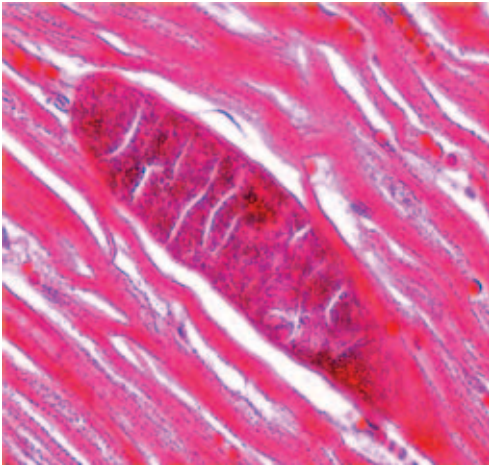


**Figure 2.** Lung alveolar collapsed, oedematous

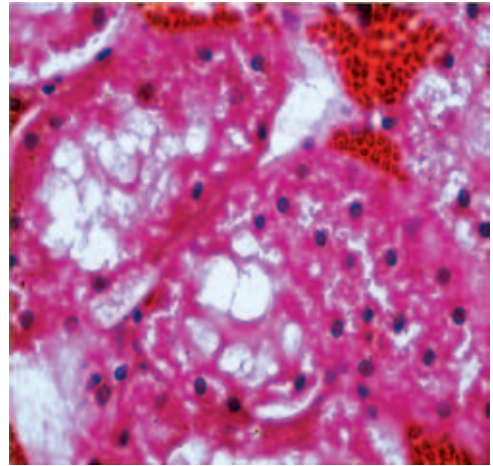


**Figure 3.** Severe congestion, infiltration of few PMNs and congested (X10, H&E) in alveolar interstitium (X10, H&E)





**Figure 4.** *Sarcocystis* spp. formed in intra-cardiac muscle



**Figure 5.** Infiltration of RBCs, necrosis of tubular and presence of rbc (X100, H&E) epithelia cells (X100, H&E)

tubules indicating mild necrosis effect and urine sediments were seen. There was also a material such as fibrin appearing in the renal tubular tissue.

## DISCUSSION

Based on the clinical signs, pathology and parasitology findings, a case of Oestrosis due to *Oestrus ovis* was confirmed. No significant bacteria were isolated from any organs. This may be due to prompt antibiotic treatment that reduces the chances for bacterial isolation. In reviewing the histopathology findings, there was severe pulmonary congestion, moderate to severe pulmonary oedema involving lung. Centrilobular hepatic necrosis had taken place in the liver tissue. Moderate to severe renal tubular necrosis was found in the kidney tissue. Myocardial sarcocystosis with mild congestion in heart muscle. The sheep also showed chronic helminthiasis

problem. There was no significant bacterial growth except *Staphylococcus* spp. from the organ specimen as the sheep has been treated.

In summary, there was severe pulmonary congestion and mild pneumonia due to parasitic infestation and secondary bacterial infection. In this case, only one mature larvae (L3) of *Oestrus ovis* was recovered from the sheep during post mortem; this could be due to the possibility that in adult sheep, many L1 are destroyed by immune reactions, as indicated by Bart and Minar (1992) and Marchenko and Marchenko (1989). The first stage larva (L1) stage is more commonly found in sheep less than 1 year of age due to the existence of a period of hypobiosis. The larvae also may adapt to local climatic conditions while in the L1 stage during hypobiosis period. Consequently, the antigenic stimulation related to reinfestations and to the moulting of the larvae in the upper respiratory cavities

induces a strong immune reaction. First stage larvae are very sensitive to immune reactions as indicated by Bart and Minar (1992) and Marchenko and Marchenko (1989, 1994) and larvae could be destroyed during moulting, resulting in low numbers of third stage larvae. Furthermore, the low prevalence of third stage larvae could be due to the rate of development and the brief duration of third stage larvae in the sinuses before they are expelled.

Usually older animals are more likely to have heavier infestations, which is similar to the data for sheep reported by Abo-Shehada *et al.* (2000.) Sheep may be predisposed to this problem as reported by Dorchies *et al.* (1998) who reported that there might be an “ovine” strain and a “caprine” strain. Despite the fact that both animal species can be hosts of this parasite, infection prevalence and larval burdens are generally higher in sheep than in goats after either natural or artificial infection (Duranton *et al.*, 1996; Papadopoulus *et al.*, 2006), and this is taken to indicate higher susceptibility in sheep. Besides that, many factors influence the larval populations of *O. ovis* found in the skull cavities of goats; the most important is climate which affects the number of larviparous females to which the animal have been exposed (Yilma and Dorchies, 1993). This may be due to the weather condition at high altitudes which are not favourable for the presence and development of *O. ovis*, as described Bergeaud *et al.* (1994). When environmental conditions are adverse, larvae cease their development during the

hypobiotic period (Cobbett and Mitchell, 1941; Horak, 1981). The stocking density of the flock will also influence the infection of *O. ovis*.

Differing degrees of clinical signs can be classified as mildly affected, moderately, as well as severely affected. More parasites recorded in the presence of purulent discharge is in agreement with previous observation in sheep (Abo-Shehada *et al.*, 2000). Dorchies *et al.* (1998) described pathology consistent with hypersensitivity responses in the affected animals. Contrary to this case, no sheep has been exhibiting purulent discharge, except mucopurulent discharge. Nevertheless, some authors associated such responses with immunopathology, and suggested that the presence of *O. ovis* larvae have an immunosuppressive effect. The hypobiotic survival of larvae during the hot or dry season is associated with a sharp decrease in the severity of local reactions until the first instar larvae resume their development. Furthermore, the pathological changes were associated with burdens of live and dead larvae, suggesting that they played an active role in the pathology. However, the pathological effects are often underestimated because owners and veterinarians are used to seeing the infection. But, the study of natural and experimental infections has provided information about the evolution of the disease and its pathophysiology. Hypersensitivity is involved; the numbers of mast cells and eosinophils increase but changes in IgE have only recently been

examined. And, there will be important inflammatory cell infiltration against the larvae in the sinu-nasal cavities as reported by Dorchies *et al.* (1998) and Nguyen *et al.* (1999).

In this case, no dewormer was administered prior to importation and upon arrival. Only the antistress medication was given to the sheep. Prompt use of avermectin (e.g. Ivermectin/Doramectin injection) may have reduced the *O. ovis* burden in the sheep together with other sheep parasites or helminthiasis. Prognosis must be guarded if the animal showed severe pneumonia and breathing difficulties. Antibiotics may be needed should animal become pyrexia. In terms of diagnosis, the newly imported sheep must be examined with endoscope and faecal larvae examination to determine the possibility of carrying *Oestrus ovis*. A complete serological diagnosis for other concurrent diseases can also be conducted as severe Oestosis can cause a reduction in immunity and hence predispose the animal to other disease. Serology for oestrosis also can be done and is available. Usually the seropositive animal correlated with flock size, as many other authors have reported (Gupta *et al.*, 1985; Marchenko and Marchenko, 1989; Ribeiro *et al.*, 1990). This may be due to possible higher risk of infestation and reinfestation among herds of greater number of susceptible animals that are crowded together.

In accordance with *O. ovis* infection, proper identification / morphology diagnosis of this larvae using Zumpt, 1965 keys is important. More surveillance in

abattoir should be carried out to locate the larval stage in upper respiratory tract, determine the infestation rate and prevalence in goat or sheep. The *Oestrus ovis* has immunosuppressive effects with consequent association with respiratory pathogen, (Dorchies *et al.*, 1993). The naso-sinusal myiasis caused by *O. ovis* is common in both sheep and goats, and is likely to be of importance to animal production and welfare.

## CONCLUSION

In conclusion, this is a case of **Oestrosis** caused by *Oestrus ovis* infection in the upper respiratory tract with histopathology findings of severe pulmonary congestion and mild pneumonia in the crossbred Damara sheep. The mortality and morbidity in the flock is low as no apparent correlation was noted with other sheep which exhibited clinical signs and there was no recovery of larvae from the rest of the animals. This disease caused by *Oestrus ovis* larvae needs further study in terms of chronobiology and prevalence (seroprevalence rate), potential risk factors associated with the myiasis in sheep, seasonal variations in the life cycle and the association between larvae and the weather condition. The pathophysiology of *Oestrus ovis* in sheep and hypersensitivity results in an immunodeficient state will also need to be studied. In Malaysia, this is a rare case of myiasis which needs further attention especially for prevention and control of an



emerging new infection which may be a threat to local livestock farming.

## ACKNOWLEDGEMENT

The author would like to thank the ex-Director and MVK Kuantan staff (pathology, parasitology and bacteriology section) as well as Veterinary Officer from TAC Jengka for their help and expertise in diagnosing this case. Last but not least, the Institute of Medical Research (Entomology Unit) and Dr. Krishnamoorthy (Consultant Entomologist) in assisting with the the identification of the larvae.

## REFERENCES

1. Abo-Shehada, M.N. *et al.*, 2000. Age and seasonal variations in the prevalence of *O. ovis* larvae among sheep in northern Jordan. *Prev. Vet. Med.* **47**: 205-212.
2. Alcaide, M. *et al.*, 2003. Seasonal variations in the burden distribution of *Oestrus ovis* in sheep in the southwest of Spain. *Vet. Parasitol.* **118**: 235-241.
3. Amr, Z.S. *et al.*, 1993. Ophthalmomyiasis externa caused by *Oestrus ovis* L. in the Aljoun area of northern Jordan. *Ann. Trop. Med. Parasitol.* **87**: 259-262.
4. Berrag, B. *et al.*, 1996. Parasites of goats in the north of Morocco. In: Proceedings of the IFS Workshop, Burkina Faso. *Parasitol. Res. Afr.* 287-306.
5. Biu, A.A. *et al.*, 1999. Incidence of *Oestrus ovis* infestation in Borno-White Sahel goats in the semi-arid zone of Nigeria. *Vet. Res.* **30**: 109-112.
6. Breev, K.A. *et al.*, 1980. Influence of constant and variable temperature on pupal development of the sheep bot fly (*Oestrus ovis* L.). *Folia Parasitol.* **27**: 350-365.
7. Cobbett, N.G. *et al.*, 1941. Further observations on the life cycle and incidence of the sheep bot, *O. ovis*, in New Mexico and Texas. *Am. J. Vet. Res.* **2**: 358-366.
8. Dar, M.S. *et al.*, 1980. Ophthalmomyiasis caused by the sheep nasal bot *Oestrus ovis* (Oestridae) larvae, in the Benghazi area of Eastern Libya. *Trans. Roy. Soc. Trop. Med. Hyg.* **74**: 303-306.
9. Dorchies, Ph. *et al.*, 1993. Prevalence of lung abscesses and interstitial pneumonia in ovine Oestrosis. *Vet. Rec.* **133**: 325.
10. Dorchies, P. *et al.*, 1997. *L'oestrus ovine*: revue. *Rev. Med. Vet.* **148**:565-574.
11. Dorchies, P. *et al.*, 1998. Pathophysiology of *Oestrus ovis* infection in sheep and goats: a review. *Vet. Rec.* **142**: 487-489.
12. Dorchies, Ph. *et al.*, 1999. Oestrose du mouton et de la chevre (*Oestrus ovis* Linne 1761) en Afrique: resultants d' une enquete sur 3204 serums provenant de neuf pays. *Rev. Med. Vet.* **150**: 463-466.
13. Dorchies, Ph *et al.*, 2000. *Oestrus ovis* (Linne 1761) in sheep and goats in south of France. *Vet. Parasitol.* **8**: 269-273.
14. Dorchies, P. *et al.* 2000. Prevalence and larval burden of *Oestrus ovis* (Linne 1761) in sheep and goats in northern Mediterranean region of France. *Vet. Parasitol.* **88**: 269-273.
15. Gupta, J.R. *et al.*, 1985. Bionomics of *Oestrus ovis* (sheep nasal fly). *Indian Vet. Med. J.* **9**: 71-75.
16. Horak, I.G. *et al.*, 1981. The similarity between arrested development in parasitic nematodes and diapauses in insects. *J.S. Afr. Vet. Assoc.* **52**: 299-303.
17. Jagannath, M.S. *et al.*, 1989. Factors influencing *Oestrus ovis* infestation in sheep and goats. *Curr.res.* **18**, 118-119.
18. Mantovani *et al.*, 1966. Ricerche sui parassiti degli ovine della Marsica. *Parassitologia* **8**: 103-110.
19. Mantovani, A. *et al.*, 1964. Prime ricerche sulle parassitosi delle pecore delle Marsica. *Atti soc. It. Sci. Vet.* **8**: 441-442.
20. Marchenko, V.A.m Marchenko, V.P., 1989. Survival of *Oestrus ovis* larvae depends on the state of the immune system of sheep. *Parazitologiya* **2**: 129-133.
21. Murguia, M *et al.*, 2000. Detection of *Oestrus ovis* and associated risk factors in sheep from the central region of Yucatan, Mexico. *Vet. Parasitol* **8**: 73-78.
22. Marsodi, M. *et al.*, 2003. The respiratory and allergic manifestation of human myiasis caused by larvae of the sheep bot fly (*Oestrus ovis*): a report of 33 pharyngeal cases from southern Iran. *Ann. Trop. Med. Parsitol.* **97**, 75-81.
23. Omar, M.S. *et al.*, 1988. External ophthalmomyiasis due to the sheep nostril bot fly larva *Oestrus ovis* in Saudi Arabia. *Ann. Trop. Med. Parasitol.*, **82**, 221-223.
24. Trezeguet, M.A., 1996. Prevalencia de enfermedades en 4000 majadas caprinas en los departamentos Atamisqui, Ojo de Agua, Que brachos y Salavina province de Santiago del Estero, Republica de Argentina. *Vet. Argentina* **13**, 485-489.
25. Yilma, J.M. 1993. Essays d' infestations experimentales de l' agneau par larves I d' o.ovis. *bull. Soc. France Parasitol.* **43**, 43-47.
26. Zumpt, F. 1963. Ophthalmomyiasis in man with special reference to the situation in Southern Africa. *Sout Afr. Med J.* **37**, 425-428.
27. Zumpt, P., 1965. *Myiasis in Man and Animals in the Old World*, Butterworth et Co., London, 257 pp.